

RESEARCH ARTICLE

Evaluation of the Effects of New Combined Adsorbent on Occurrence of Pathological Lesions in Aflatoxin B1-Challenged Broiler Chickens

Biljana DJURDJEVIĆ^{1,a(*)} Marko PAJIC^{1,b} Slobodan KNEŽEVIĆ^{1,c} Vladimir POLAČEK^{1,d}
Ksenija NEŠIĆ^{2,e} Ivana VUČIĆEVIĆ^{3,f} Dušica OSTOJIC ANDRIĆ^{4,g}

¹ Scientific Veterinary Institute "Novi Sad", Department for Epizootiology, Clinical Diagnostic and DDD, 21000 Novi Sad, SERBIA

² Scientific Veterinary Institute of Serbia, Department of Food and Feed Quality and Safety, 11070 Belgrade, SERBIA

³ University of Belgrade, Faculty of Veterinary Medicine, Department of Pathology, 11000 Belgrade, SERBIA

⁴ Institute for Animal Husbandry, Department of Animal Breeding and Genetics, 11080 Zemun-Belgrade, SERBIA

ORCID: ^a 0000-0002-1705-7615; ^b 0000-0003-4221-2602; ^c 0000-0001-6316-5863; ^d 0000-0002-7413-7902; ^e 0000-0001-9255-3187

^f 0000-0003-3064-4248; ^g 0000-0002-6913-4475

Article ID: KVFD-2021-26654 Received: 16.10.2021 Accepted: 16.01.2022 Published Online: 16.01.2022

Abstract: This experiment was performed to investigate the protective effect of a new combined adsorbent (bentonite + yeast cell wall extract) previously tested *in vitro*, on the occurrence of pathological lesions in broilers fed a diet contaminated with aflatoxin B1 until 21 days of age. A total of 96 one-day old Ross 308 hybrid broiler chickens were divided into four groups: group I (control), group II (5 g/kg adsorbent), group III (5 g/kg adsorbent + 2 mg/kg aflatoxin B1), and group IV (2 mg/kg aflatoxin B1). Grossly, AFB1 and AFB1+adsorbent fed birds showed enlargement, friable texture of liver and enlargement and pallor of kidneys. Spleen revealed size reduction. No gross-pathological changes were observed in control and group II. Histopathologically, lesions were observed in aflatoxicated groups. Liver revealed vacuolar cell degeneration, periportal and perivascular infiltration of mononuclear cells. Kidneys revealed mild to moderate degree of haemorrhages, tubular epithelial necrosis and infiltration of mononuclear cells along with heterophils. In group IV, catarrhal enteritis characterized by desquamation of epithelial cells were found in the duodenum. A milder form of gross and histopathological lesions was seen in group III. In conclusion, the present study revealed that supplementation of a new combined toxin binder product in the concentration of 5 g/kg could not completely ameliorate aflatoxicity in broilers, although it met the stringent European regulation requirements for the minimum of 90% aflatoxin binding efficiency in *in vitro* study.

Keywords: Adsorbent, Aflatoxin B1, Broilers, Pathological lesions

Aflatoxin B1 Verilen Etlik Piliçlerde Yeni Kombine Adsorbanın Patolojik Lezyonların Oluşumuna Etkilerinin Değerlendirilmesi

Öz: Bu çalışma, daha önce *in vitro* olarak test edilen yeni bir birleşik adsorbanın (bentonit + maya hücre duvarı ekstraktı), 21 günlük yaşa kadar aflatoxin B1 ile kontamine edilmiş bir diyetle beslenen etlik piliçlerde patolojik lezyonların oluşumu üzerine koruyucu etkisinin araştırılması için yapıldı. Toplam 96 adet bir günlük Ross 308 hibrit etlik piliç, grup I (kontrol), grup II (5 g/kg adsorban), grup III (5 g/kg adsorban + 2 mg/kg aflatoxin B1) ve grup IV (2 mg/kg aflatoxin B1) olmak üzere dört gruba ayrıldı. Büyük ölçüde, AFB1 ve AFB1+adsorban verilmiş piliçlerde karaciğerde büyüme ve gevrek bir doku ve böbreklerde büyüme ve solgunluk görüldü. Dalağın boyutunda küçülme saptandı. Kontrol ve grup II'de açık patolojik değişiklikler gözlenmedi. Aflatoxin verilen gruplarda histopatolojik lezyonlar izlendi. Karaciğerde vakuolar hücre dejenerasyonu, mononükleer hücrelerin periportal ve perivasküler infiltrasyonu görüldü. Böbreklerde, hafif ile orta derecede kanamalar, tübüler epitel nekrozu ve heterofillerle birlikte mononükleer hücre infiltrasyonu saptandı. Grup IV'te duodenumda epitel hücrelerde deskuamasyon ile karakterize kataral enterit saptandı. Grup III'te daha hafif açık ve histopatolojik lezyonlar görüldü. Sonuç olarak, bu *in vitro* çalışma, 5 g/kg konsantrelili yeni bir kombine toksin bağlayıcı ürünün eklenmesinin, etlik piliçlerde aflatoksikozisi tamamen iyileştirmedeğini, ancak Avrupa'daki minimum %90 aflatoxin bağlama etkinliği için katı düzenleme şartlarını karşıladığını ortaya koydu.

Anahtar sözcükler: Adsorban, Aflatoxin B1, Broiler, Patolojik lezyonlar

How to cite this article?

Djurđević B, Pajić M, Knežević S, Polaček V, Nešić K, Vučićević I, Ostojić Andrić D: Evaluation of the effects of new combined adsorbent on occurrence of pathological lesions in aflatoxin B1-challenged broiler chickens. *Kafkas Univ Vet Fak Derg*, 28 (2): 185-191, 2022.
DOI: 10.9775/kvfd.2021.26654

(*) Corresponding Author

Tel: +381 648185487 Cellular phone: +381 214895317 Fax: +381 21518544

E-mail: biljana@niv.ns.ac.rs (B. Djurdjević)



This article is licensed under a Creative Commons Attribution-NonCommercial 4.0 International License (CC BY-NC 4.0)

INTRODUCTION

Mycotoxins represent toxic secondary metabolites of a wide range of fungi (principally molds) and have adverse effects on human and animal health. They cause a variety of acute or chronic diseases, collectively called “mycotoxicoses”. There are over 400 identified mycotoxins [1] while aflatoxins, zearalenone, ochratoxin A, fumonisins, trichothecenes (such as deoxynivalenol - DON), and T-2 toxin are some of the mycotoxins that can significantly impact health and productivity of farm animals, including poultry species [2].

Since their first identification in the early 1960s, aflatoxins (AF) have been the most studied class of mycotoxins. The cause of aflatoxicosis in poultry and other food-producing animals has been attributed to the ingestion of various feeds contaminated with *Aspergillus* spp., and among the six types of aflatoxins, aflatoxin B1 (AFB1) is considered as the most potent and extremely toxic metabolite of this fungus [3]. Besides that, aflatoxin B1 is the most common metabolite in feeds and foods [4].

Aflatoxins cause a variety of adverse effects on the poultry health, including poor growth performance, disturbed gastrointestinal tract, immunosuppression, decreased weight gain, poor feed efficiency, reduced egg production and egg weight, changes in organ weights, and as well as carcinogenic, mutagenic and teratogenic effects [2,4-6]. The clinical signs and pathological changes caused by AFB1 in poultry have been widely described [2,7,8]. AFB1 causes a series of pathological changes in the organism and common pathological findings include the changes in the liver such as hepatomegaly, paleness, hydropic degeneration, fatty change, bile-duct hyperplasia and periportal fibrosis, kidney and spleen lesions and lesions in immune organs [9]. Sometimes there are no visible clinical signs and post-mortem lesions of mycotoxin intoxication, since in most cases, mycotoxicosis is chronic and caused by low-level ingestion of fungal metabolites, resulting in a decline in performance and the occurrence of nonspecific changes [2]. Usually, farm animals exhibit symptoms of chronic mycotoxicoses when exposed to feed contaminated with toxins below the guide-line levels [10].

Although there are a lot of innovative strategies for the reduction of mycotoxins in feed [11], one of the most common approaches to their detoxification includes the use of diverse mycotoxin binders [12]. The role of these inert adsorbents is to bind and immobilize mycotoxins in the gastrointestinal tract of animals, thus reducing their bioavailability and distribution to blood and target organs [13]. Since many of the studied adsorbents are expensive and may not be economically accessible for small farmers in developing countries, it is therefore important to investigate the use of locally available adsorbents for poultry feed decontamination [14].

Although Serbian national legislation regarding mycotoxins is harmonized with European legislation, only a small number of systematic monitoring programs are implemented and this cannot provide precise data about the occurrence of mycotoxins in feed in Serbia [15]. However, according to some previous studies, the presence of AF in corn from Serbia showed high contamination levels in corn and feed [16,17], and based on these results, it is known that AFB1 is frequently found in the corn originating from the province of Vojvodina, the north of Serbia.

From the point of view of diagnostic interest, the objectives of this study were to evaluate the gross and pathohistological lesions in different organs of broilers fed the diet that was experimentally contaminated with 2 mg/kg AFB1 and to determine the effectiveness of the new combined adsorbent on the appearance of pathological lesions in target organs. The other aim of this study was also a comparison of *in vitro* preliminary tests [18] of adsorption efficiency of new mineral adsorbent and an *in vivo* broiler trial.

MATERIAL AND METHODS

Experimental Design and Birds

The experiment was performed at the Institute for Animal Husbandry (Belgrade-Zemun). It was approved by Institute's Ethical Committee (Decision no. 323-07-03195/2020-05) and performed in accordance with the recommendations of the European Commission Directive 2010/63 EEC [19] and the Serbian Law on Animal Welfare [20]. A total of 96 one-day-old unsexed broilers (Ross 308 hybrid) were obtained from a local commercial hatchery. The birds were maintained in pens and divided into 4 equal groups - 24 per group, with 4 replicates of 6 birds each. The pen was the experimental unit. The chickens were exposed to 24 h of light every day. The temperature inside the experimental facility was initially 32±1°C and was gradually reduced by 3°C per week. Water and feed were given *ad libitum*. The chicks were inspected daily and any health-related problems were recorded. No vaccinations were administered during the experiment period.

Feeding Trial

Crystalline aflatoxin B1 with 99% purity used in this experiment was produced by Acros Organics™ (Geel, Belgium). Crystalline aflatoxin B1 was mixed with 1 kg ground corn using drum mixer RRM mini II (J. Engelsmann AG) for 5 min. Aflatoxin mixed ground corn was added to a basal diet to provide the required amount of 2 mg/kg feed. The used novel combined experimental adsorbent consisted of bentonite (smectite - dioctahedral montmorillonite) with yeast cell wall extract. This adsorbent was selected based on the adsorption characteristics obtained in *in vitro* studies [18]. Mycotoxin adsorbent was incorporated into the basal diet using counter-current

horizontal mixers. The experiment lasted for 21 days, and the broilers were fed a starter (from 1 to 14 days of age) and a grower (from 15 to 21 days of age). The chicks were randomly divided into four groups and each bird was weighed once a week. Group 1 (GI) served as a control group; group 2 (GII) received feed containing 5 g adsorbent/kg each day; group 3 (GIII) received 5 g adsorbent/kg + 2 mg AFB1/kg each day; group 4 (GIV) received feed containing 2 mg AFB1/kg, also for 21 days. The starter and grower feed for the experimental birds were tested for any possible residual aflatoxins and other mycotoxins, as described by Serbian legislation [21].

Gross Pathology and Histopathological Analysis

On the 21st day of the experiment, all the birds from groups were euthanized using carbon dioxide and then dissected. All the animals were weighed before euthanasia. Detailed necropsies were conducted immediately after killing the birds and gross lesions were reported. Additionally, for histopathological studies, tissue samples of the liver, kidneys, bursa of Fabricius, and duodenum were removed and collected in 10% neutral buffered formalin for 72 h. After fixation, the samples were dehydrated in ascending grades of ethanol, cleared in xylene and embedded in paraffin. Five μm thick tissue sections were cut with a microtome and mounted on a glass slide. The slides were stained with hematoxylin and eosin (H&E) and examined under an Olympus light microscope (Olympus, BX51 Tokyo, Japan) for histopathological changes.

Histomorphometric Analysis

Histomorphometric analyses were done to evaluate the height of the duodenal villi. The same segment of the duodenum from each bird in the group was sampled (approximately 1 cm segment from the middle part of the duodenum was dissected). Using the light microscopy 10 x objective lens, ten well-oriented villi from each duodenum were randomly selected. The measurements were performed using the Olympus BX51 microscope with a digital CCD camera (Color View III, Olympus) connected

to a computerized image analysis system (Olympus Cell B, Olympus, Japan). The length of the duodenal villi (expressed in μm) was measured from the villus-crypt junction to the top of the villi.

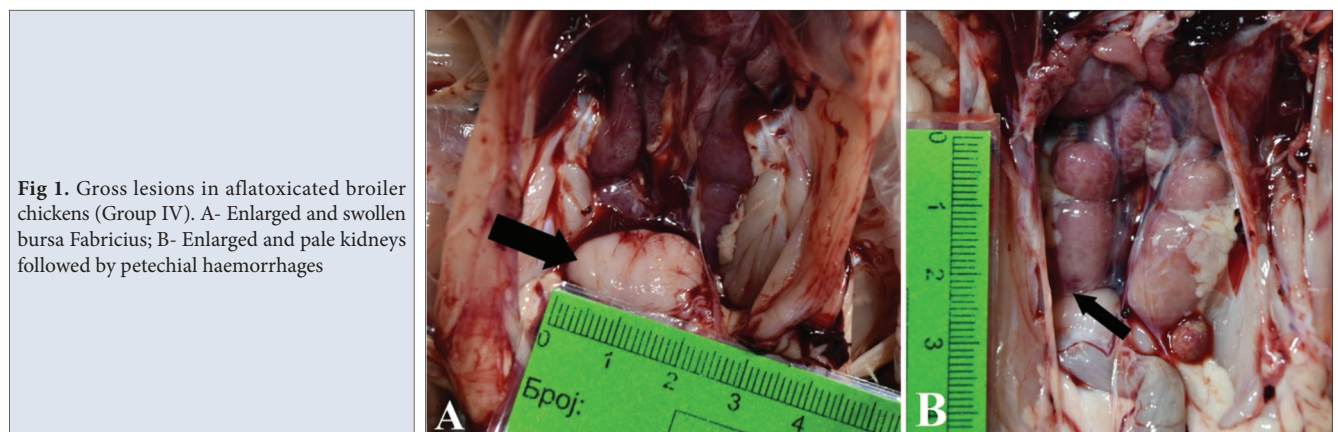Statistical Analysis

Statistical analysis was performed using R version 3.2.2 statistical software (R Foundation for Statistical Computing, Vienna, Austria). The data were analyzed using one-way models of analysis of variance (ANOVA). Significant differences between the groups were set at $P \leq 0.05$ and probabilities were determined by Duncan's post hoc test.

RESULTS

Gross Lesions

No mortalities occurred during the experiment period and in general, all the birds were in good condition. The birds belonging to Group I (Control) had a normal morphological appearance of all the organs throughout the experimental study. In the birds from Group II (GII), the only detected macroscopic lesion was the hypertrophy of bursa Fabricius in 2 chickens. Livers were normal in color, size and consistency in all chicks from groups GI and GII. The constant gross lesions in the intoxicated birds from groups III and IV were atrophy of the spleen and hypertrophy of bursa Fabricius. The birds from group III showed moderate enlargement and congestion of the liver and moderate enlargement of kidneys. The most striking macroscopic lesions were in aflatoxin-fed group IV (GIV). The majority of birds had enlarged and edematous bursa Fabricius (*Fig. 1-A*), enlarged kidneys and livers. The liver was congested, swollen and friable and occasionally small yellowish foci were seen. Enlarged kidneys were mostly pale (*Fig. 1-B*), and the presence of petechial and ecchymotic hemorrhages was detected. Mild hemorrhages were occasionally present in the mucosa of the small intestines. The heart and subcutaneous tissues were normal in appearance and no other macroscopic lesions



Lesions		Groups			
		Group I	Group II	Group III	Group IV
Enlargement of organs	Liver	-	-	5/24	9/24
	Kidney	-	-	8/24	15/24
	Bursa Fabricius	-	2/24	5/24	13/24
Hemorrhages	Liver	-	-	3/24	7/24
	Kidney	-	-	3/24	6/24
	Intestine	-	-	3/24	8/24
	Spleen	-	2/24	5/24	7/24
Friable liver		-	-	5/24	8/24
Pallor kidneys		-	-	8/24	12/24
Spleen atrophy		-	-	5/24	9/24

Legend: no change/lesion (-); The values represent the birds showing gross lesions/number of birds examined in each experimental group

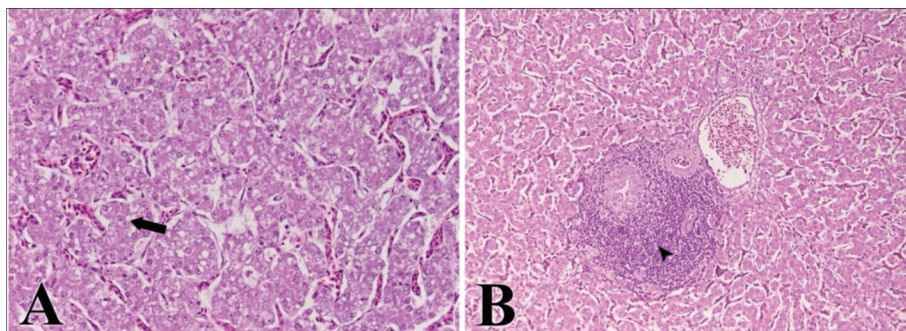


Fig 2. Liver of broiler (Group IV) fed with 2 mg AFB1/kg, 21st day of intoxication. A- Degeneration of hepatocytes having vacuolated cytoplasm (arrow), HE x 400; B- Pericholangitis (arrowhead), HE x 200

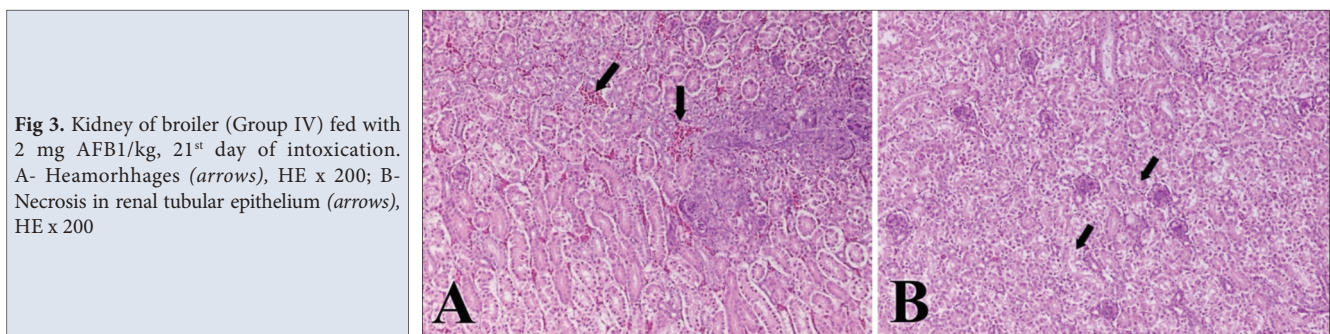


Fig 3. Kidney of broiler (Group IV) fed with 2 mg AFB1/kg, 21st day of intoxication. A- Hemorrhages (arrows), HE x 200; B- Necrosis in renal tubular epithelium (arrows), HE x 200

were detected in all the examined birds. The detected gross lesions and their frequency in birds are in [Table 1](#).

Histopathological Lesions

The birds from groups I and II showed no histopathological alterations and normal anatomical structure was present in all birds. In the birds belonging to groups III and IV, microscopic lesions of the liver consisted of hepatic vacuolar cell degeneration ([Fig. 2-A](#)) and accumulation of a large number of heterophils and multifocal mononuclear cell infiltration in the parenchyma, as well as pericholangitis ([Fig. 2-B](#)). Less frequent lesions of the liver were perivascular infiltration and moderate to severe multifocal hemorrhages and multifocal necrotic foci. Another microscopic lesion observed in the liver of all

birds from both aflatoxicated groups was congestion of the hepatic sinusoids. Comparing both groups, the described microscopic lesions in the liver were less severe in group III. Moderate degree of sinusoidal congestion was revealed in the kidneys of aflatoxin fed birds, as well as mild to moderate focal hemorrhages ([Fig. 3-A](#)), mild to moderate tubular epithelial necrosis ([Fig. 3-B](#)), with the infiltration of aggregates of mononuclear cells along with heterophils. The kidneys of birds from group III revealed mild degree of congestion and mild degree of tubular epithelial necrosis. The spleens were hyperemic, and reactive hyperplasia of secondary follicles was revealed, resulting in the widening of a lymphoid component. In group IV, catarrhal enteritis characterized by desquamation of epithelial cells was found in the duodenum. No lesions were observed in bursa

Table 2. Histomorphometric values of duodenal villi length of broiler chickens on the 21st day of experiment

Group	Length of Duodenal Villi (µm)
Group I	974.11±162.21 ^a
Group II	972.85±155.06 ^a
Group III	981.49±145.68 ^a
Group IV	819.32±193.29 ^b

Means within the same column with no common superscript letter are significantly different ($P < 0.05$). Data are means with standard deviation

of Fabricius that could be interpreted as a characteristic of the process.

Histomorphometric Observation

Histomorphometric observations are presented in *Table 2*. There was a significant difference ($P < 0.05$) in the length of duodenal villi between group IV and other treatment groups and control group. There was no significant difference between treatment groups (group II and III) and control group.

DISCUSSION

The majority of the research is focused on the decontamination and detoxification of feed from aflatoxin B₁, since their frequent occurrence in feedstuffs cause severe health problems in the poultry industry and large economic losses. *In vitro* preliminary tests of mycotoxin adsorbents are considered as a powerful tool for screening the potential of mycotoxin-detoxifying agents since if no adsorption occurs *in vitro*, there is little or no chance to do so *in vivo* [22]. In this study, the ability of a new combined mycotoxin adsorbent to detoxify poultry feeds contaminated with aflatoxin B₁ was tested in *in vivo* broiler trial. The absence of pathological lesions in birds from the control group and birds fed on adsorbent alone indicate that the new combined adsorbent is non-toxic and inert. Similar observations were made by Manafi et al. [23], Lakkawar et al. [24] and Ortatatli and Oguz [25] who reported that the chicks after receiving binders alone did not have any pathological changes. The harmful consequences of AFB₁ administration on the pathological lesions of chickens are widely reported, and many studies showed that naturally-contaminated diets cause the most harm to the birds [26]. The adverse effects reported earlier have also been identified in the experimental feeding of AFB₁ in the present study.

In poultry, aflatoxin B₁ mostly affects the liver, kidney, immune organs (spleen, bursa of Fabricius and thymus) and gastrointestinal system. Considering that liver is a major metabolizing and detoxifying organ in the body, the exposure to AFB₁ leads to liver damage in different animal species [27] causing various pathological changes such as enlargement, congestion, necrosis, pallor, discoloration

and fatty liver syndrome [9,28]. Prolonged exposure to aflatoxins leads to the increase in the relative mass of the liver due to increased vacuolization of hepatocytes and accumulation of large amount of lipids. In this study, liver lesions were observed in aflatoxicated birds and birds fed AFB₁ diet + adsorbent. The described liver lesions of birds from group III showed a milder degree of severity and enlargement, compared to mycotoxin treated birds. Contrary to previous findings [8,24,29], the livers examined in this study did not show any pallor or increased lipid content. The group which received adsorbent alone did not show any significant histopathological changes of the liver as was the case in control group. The main histopathological changes in the liver of birds from group III and IV included vacuolar degeneration and accumulation of lymphoid cells that is in agreement with those reported by Lakkawar et al. [24], Ahmed et al. [7], Denli et al. [30]. From previously discussed reports [7,23] as well as from our findings, it is clear that even short-term exposure to AFB₁ has negative effects in broiler chickens and induce pathological changes in the liver.

Kidneys also take part in detoxification of aflatoxins, making them very vulnerable organs to AF. The kidneys are among the organs in which aflatoxin residues are most often detected [31], making them the target organs for AF. Various studies have shown that AFB₁ leads to congestion of the renal sinusoids and an increase in the relative mass of the kidneys. Besides, AFB₁ leads to degenerative and necrotic changes in the tubular epithelium, reduction of glomerular filtration thereby impairing renal function [9]. The most common macroscopic changes in birds treated with AFB₁ are kidney enlargement with pallor [25,28,29] which is what our research has proved in the majority of the birds belonging to Group IV. Histopathological changes in the kidney of chickens exposed to AFB₁ and AFB₁ + adsorbent are comparable to those reported in the literature on avian aflatoxicosis. The birds from group III showed a milder degree of severity and enlargement of kidneys as compared to mycotoxin treated birds.

Since the gastrointestinal tract (GIT) is the major spot of conversion and absorption of food components, it is expected that the negative effects of mycotoxins will be manifested to a greater extent in the organs of the GIT. However, the available literature data on the effect of mycotoxins on GIT organs of poultry are scarce, and the results of the researches are controversial [32,33]. Such discrepancies can be explained by the fact that various poultry species were used in the studies, different parts of the GIT were examined as well as the doses of AFB₁ and lengths of exposure varied [9]. In this study, pathohistological lesions of the intestine were detected only in the chickens exposed to AFB₁. Catarrhal enteritis with epithelial desquamation was observed. Similar results were reported by Kumar and Balachandran [34]. Moreover,

our results prove that AFB1 in the quantity of 2 mg/kg leads to shortening of the duodenal villi, which is in agreement with the results of Yang et al.^[35]. Likewise, the same findings in duodenum were reported in turkeys naturally intoxicated with deoxynivalenol^[36]. On the other hand, some authors did not observe any significant histological lesions in intestinal epithelium in broiler chickens intoxicated with AFB1^[33,37]. Another group of authors has proved that the use of AFB1 in large doses does not lead to histopathological changes of intestines^[33,38]. Based on the literature available and aforementioned studies, the response of the gastrointestinal tract to the aflatoxin B1 is non-conclusive, and it is difficult to determine a dose-effect relationship between AFB1 and histological changes in the intestines of the chicken.

In various studies conducted in the past decades, it has been shown that AFB1 decrease immune responses^[28,39], and as a result of AFB1-induced immunosuppression, the exposed poultry have lower resistance to secondary infections. AFB1 in poultry can cause damage on primary and secondary lymphoid organs including thymus, bursa of Fabricius, spleen, and bone marrow^[9]. Absolute and relative weights of immune organs are used to indirectly assess the immune status of birds, so the changes in their relative weights may result in altered immune function^[40]. In our study, the reduction in the size of the spleen was recorded in a majority of birds of both aflatoxicated groups. Previously it has been reported^[41] that reduced relative weight of the spleen caused by AFB1 may occur because its white pulp contains less lymphoid tissue. However, in this study, microscopical findings showed widening of the lymphoid component along with the formation of secondary lymphoid follicles, which is in agreement with Lakkawar et al.^[24]. The bursa Fabricius was enlarged in aflatoxicated birds, which is in agreement with Pandey and Chauha^[29].

Even though preliminary *in vitro* tests showed a high level of binding capacities of new combined adsorbent, *in vivo* results showed its partial success. The addition of 5 g/kg adsorbent to the diet of birds supplemented with 2 mg/kg AFB1 partially compensated the harmful effects of the aflatoxin B1 on the liver, spleen and kidney and also partially decreased the incidence of affected broilers. The duration of exposure to AFB1 and adsorbent could be more effective with an extension of the experiment that would probably cause more distinct morphological changes in target organs. Differences in *in vivo* efficacy compared to the expectations based on *in vitro* testing, indicate that *in vitro* results alone are not adequate for the evaluation of adsorbents. Comprehensively concluding, it is clear that examination of additives to lessen the impact of mycotoxins is a time-consuming and complex process that requires maximum commitment and repeated attempts to reach the best solution.

AVAILABILITY OF DATA AND MATERIALS

The datasets during and/or analyzed during the current study available from the corresponding author (B. Djurdjević) on reasonable request.

ACKNOWLEDGEMENTS

The authors cordially thank INBERG d.o.o., Belgrade, Serbia for providing tested adsorbent.

FUNDING SUPPORT

This study was funded by Ministry of Education, Science and Technological development of Republic of Serbia by the Contract of implementation and financing of scientific research work of NIV-NS in 2021, Contract No: 451-03-9/2021-14/200031 from 05/02/2021, and as a part of the project financed by the Innovation Fund of the Republic of Serbia (project number 721).

COMPETING INTERESTS

The authors declared no potential conflicts of interest with respect to the research, authorship, and/or publication of this article.

AUTHORS' CONTRIBUTIONS

BDj, MP, SK, VP, KN conceived and planned the study design. BDj drafted the manuscript. BDj, MP and SK carried out the experiment, performed necropsy, examined and described gross lesions and made substantial contribution to collection, analysis and interpretation of the data. IV worked out in histopathological analysis and made interpretation of the results. SK verified statistical analysis and made substantial contributions to interpretation of data. VP, KN and DOA made contributions to conception and design of the article, and carried out literature research. VP, MP, KN, IV and DOA read the manuscript and made corrections in the document. All authors have approved the final version of the manuscript.

REFERENCES

1. Elliott CT, Connolly L, Kolawole O: Potential adverse effects on animal health and performance caused by the addition of mineral adsorbents to feeds to reduce mycotoxin exposure. *Mycotoxin Res*, 36 (1): 115-126, 2020. DOI: 10.1007/s12550-019-00375-7
2. Murugesan GR, Ledoux DR, Naehrer K, Berthiller F, Applegate TJ, Grenier B, Phillips TD, Schatzmayr G: Prevalence and effects of mycotoxins on poultry health and performance, and recent development in mycotoxin counteracting strategies. *Poult Sci*, 94 (6): 1298-1315, 2015. DOI: 10.3382/ps/pev075
3. Marchese S, Polo A, Ariano A, Velotto S, Costantini S, Severino L: Aflatoxin B1 and M1: Biological properties and their involvement in cancer development. *Toxins*, 10 (6): 214, 2018. DOI:10.3390/toxins10060214
4. Yavuz O, Özdemir Ö, Ortatli M, Atalay B, Hatipoglu F, Terzi F: The preventive effects of different doses of Glucomannan on experimental aflatoxicosis in Japanese quails. *Braz J Poult Sci*, 19 (3): 409-416, 2017. DOI: 10.1590/1806-9061-2016-0349
5. Yunus AW, Razzazi-Fazeli E, Bohm J: Aflatoxin B1 in affecting broiler's performance, immunity, and gastrointestinal tract: A review of history and contemporary issues. *Toxins*, 3 (6): 566-590, 2011. DOI:

10.3390/toxins3060566

6. Gul H, Khan S, Shah Z, Ahmad S, Israr M, Hussain M: Effects of local sodium bentonite as aflatoxin binder and its effects on production performance of laying hens. *Kafkas Univ Vet Fak Derg*, 23 (1): 31-37, 2017. DOI: 10.9775/kvfd.2016.15714
7. Ahmed MAE, Ravikanth K, Rekhe DS, Maini S: Histopathological alterations in Aflatoxicity and its amelioration with herbomineral toxin binder in broilers. *Vet World*, 2(10): 390-392, 2009.
8. Hussain Z, Khan MZ, Saleemi MK, Khan A, Rafique S: Clinico-pathological effects of prolonged intoxication of aflatoxin B₁ in broiler chicken. *Pak Vet J*, 36 (4): 477-481, 2016.
9. Mughal MJ, Peng X, Kamboh AA, Zhou Y, Fang J: Aflatoxin B₁ induced systemic toxicity in poultry and rescue effects of selenium and zinc. *Biol Trace Elem Res*, 178 (2): 292-300, 2017. DOI: 10.1007/s12011-016-0923-9
10. Wielogórska E, MacDonald S, Elliott CT: A review of the efficacy of mycotoxin detoxifying agents used in feed in light of changing global environment and legislation. *World Mycotoxin J*, 9 (3): 419-433, 2016. DOI: 10.3920/WMJ2015.1919
11. Shanakhat H, Sorrentino A, Raiola A, Romano A, Masi P, Cavella S: Current methods for mycotoxins analysis and innovative strategies for their reduction in cereals: An overview. *J Sci Food Agric*, 98 (11): 4003-4013, 2018. DOI: 10.1002/jsfa.8933
12. Bočarov-Stančić AS, Lopičić ZR, Bodroža-Solarov MI, Stanković SŽ, Janković SM, Milojković JV, Krulj JA: *In vitro* removing of mycotoxins by using different inorganic adsorbents and organic waste materials from Serbia. *Food Feed Res*, 45 (2): 87-96, 2018. DOI: 10.5937/FFR1802087B
13. Magnoli AP, Monge MP, Miazzo RD, Cavaglieri LR, Magnoli CE, Merkis CI, Cristofolini AL, Dalcero AM, Chiacchiera SM: Effect of low levels of aflatoxin B₁ on performance, biochemical parameters, and aflatoxin B₁ in broiler liver tissues in the presence of monensin and sodium bentonite. *Poult Sci*, 90 (1): 48-58, 2011. DOI: 10.3382/ps.2010-00971
14. Mgbeahuruike AC, Ejioffor TE, Christian OC, Shoyinka VC, Karlsson M, Nordkvist E: Detoxification of aflatoxin-contaminated poultry feeds by 3 adsorbents, bentonite, activated charcoal, and fuller's earth. *J Appl Poult Res*, 27 (4): 461-471, 2018. DOI: 10.3382/japr/pfy054
15. Udovicki B, Audenaert K, De Saeger S, Rajkovic A: Overview on the mycotoxins incidence in Serbia in the period 2004-2016. *Toxins*, 10 (7): 279, 2018. DOI: 10.3390/toxins10070279
16. Kos JJ, Škrinjar MM, Mandić AI, Mišan AČ, Bursić VP, Šarić BM, Janić-Hajnal EP: Presence of aflatoxins in cereals from Serbia. *Food Feed Res*, 41 (1): 31-38, 2014. DOI: 10.5937/FFR1401031K
17. Kos J, Janić Hajnal E, Šarić B, Jovanov P, Mandić A, Đuragić O, Kokić B: Aflatoxins in maize harvested in the Republic of Serbia over the period 2012-2016. *Food Addit Contam Part B Surveill*, 11 (4): 246-255, 2018. DOI: 10.1080/19393210.2018.1499675
18. Nesic K, Jaksic S, Popov N, Zivkov-Balos M, Pajic M, Zloh B, Polacek V: *In vitro* assessment of binding capacity of combined adsorbent (bentonite with yeast cell wall extracts) and aflatoxin B₁. *Arch Vet Med*, 13 (1): 41-52, 2020. DOI: 10.46784/e-avm.v13i1.65
19. European Commission: Directive 2010/63/EU of the European Parliament and of the Council of 22 September 2010 on the protection of animals used for scientific purposes. Official Journal of the European Union, 2010.
20. Zakon o Dobrobiti Životinja: Službeni Glasnik RS, 41/2009, 2009.
21. Pravilnik o Kvalitetu Hrane za Životinje: Službeni Glasnik RS, 4/2010, 113/2012, 27/2014, 25/2015, 39/2016.
22. Boudergue C, Burel C, Dragacci S, Favrot MC, Freymy JM, Massimi C, Prigen P, Debongnie P, Pussemier L, Boudra H, Morgavi D, Oswald I, Perez A, Avantiaggiato G: Review of mycotoxin-detoxifying agents used as feed additives: Mode of action, efficacy and feed/food safety. *EFSA Supporting Publications*, 6 (9): 22E, 2009. DOI: 10.2903/sp.efsa.2009.EN-22
23. Manafi M: Evaluation of different mycotoxin binders on broiler breeders induced with aflatoxin B₁: Effects on visceral organ weight and organ lesions parameters. *Adv Environ Biol*, 5 (13): 3795-3799, 2011.
24. Lakkawar AW, Sathyanarayana ML, Narayanaswamy HD, Yathiraj S, Shridhar NB, Krishnaveni N: Effects of Diatomaceous earth in amelioration of aflatoxin induced patho-morphological changes in broilers. *Indian J Vet Pathol*, 39 (2): 154-163, 2015. DOI: 10.5958/0973-970X.2015.00035.8
25. Ortatatlı M, Oğuz H: Ameliorative effects of dietary clinoptilolite on pathological changes in broiler chickens during aflatoxicosis. *Res Vet Sci*, 71 (1): 59-66, 2001. DOI: 10.1053/rvsc.2001.0487
26. Santos RR, Oosterveer-van der Doelen MAM, Tersteeg-Zijderveld MHG, Molist F, Mézes M, Gehring R: Susceptibility of broiler chickens to deoxynivalenol exposure via artificial or natural dietary contamination. *Animals*, 11 (4): 989, 2021. DOI: 10.3390/ani11040989
27. Rawal S, Kim JE, Coulombe Jr R: Aflatoxin B₁ in poultry: Toxicology, metabolism and prevention. *Res Vet Sci*, 89 (3): 325-331, 2010. DOI: 10.1016/j.rvsc.2010.04.011
28. Abidin Z, Khatoon A, Numan M: Mycotoxins in broilers: Pathological alterations induced by aflatoxins and ochratoxins, diagnosis and determination, treatment and control of mycotoxicosis. *Worlds Poult Sci J*, 67 (3): 485-496, 2011. DOI: 10.1017/S0043933911000535
29. Pandey I, Chauhan SS: Studies on production performance and toxin residues in tissues and eggs of layer chickens fed on diets with various concentrations of aflatoxin AFB₁. *Br Poult Sci*, 48 (6): 713-723, 2007. DOI: 10.1080/00071660701713534
30. Denli M, Blandon JC, Guynot ME, Salado S, Perez JF: Effects of dietary AflaDetox on performance, serum biochemistry, histopathological changes, and aflatoxin residues in broilers exposed to aflatoxin B₁. *Poult Sci*, 88 (7): 1444-1451, 2009. DOI: 10.3382/ps.2008-00341
31. Fernández A, Verde MT, Gascón M, Ramos JJ, Gómez J: Aflatoxin and its metabolites in tissues from laying hens and broiler chickens fed a contaminated diet. *J Sci Food Agric*, 65 (4): 407-414, 1994. DOI: 10.1002/jsfa.2740650407
32. Kana JR, Tegua A, Tchoumboue J: Effect of dietary plant charcoal from *Canarium schweinfurthii* Engl. and maize cob on aflatoxin B₁ toxicosis in broiler chickens. *Adv Anim Biosci*, 1 (2): 462-463, 2010. DOI: 10.1017/S2040470010000841
33. Yunus AW, Ghareeb K, Abd-El-Fattah AAM, Twaruzek M, Böhm J: Gross intestinal adaptations in relation to broiler performance during chronic aflatoxin exposure. *Poult Sci*, 90 (8): 1683-1689, 2011. DOI: 10.3382/ps.2011-01448
34. Kumar R, Balachandran C: Histopathological changes in broiler chickens fed aflatoxin and cyclopiazonic acid. *Vet Arhiv*, 79 (1): 31-40, 2009.
35. Yang J, Bai F, Zhang K, Lv X, Bai S, Zhao L, Peng X, Ding X, Li Y, Zhang J: Effects of feeding corn naturally contaminated with AFB₁ and AFB₂ on performance and aflatoxin residues in broilers. *Czech J Anim Sci*, 57 (11): 506-515, 2012.
36. Girish CK, Smith TK: Effects of feeding blends of grains naturally contaminated with Fusarium mycotoxins on small intestinal morphology of turkeys. *Poult Sci*, 87 (6): 1075-1082, 2008. DOI: 10.3382/ps.2007-00379
37. Kubena LF, Harvey RB, Bailey RH, Buckley SA, Rottinghaus GE: Effects of a hydrated sodium calcium aluminosilicate (T-Bind) on mycotoxicosis in young broiler chickens. *Poult Sci*, 77 (10): 1502-1509, 1998. DOI: 10.1093/ps/77.10.1502
38. Kana JR, Tegua A, Mungfu BM, Tchoumboue J: Growth performance and carcass characteristics of broiler chickens fed diets supplemented with graded levels of charcoal from maize cob or seed of *Canarium schweinfurthii* Engl. *Trop Anim Health Prod*, 43(1): 51-56, 2011. DOI: 10.1007/s11250-010-9653-8
39. Hoerr FJ: Clinical aspects of immunosuppression in poultry. *Avian Dis*, 54 (1): 2-15, 2010. DOI: 10.1637/8909-043009-Review.1
40. Fouad AM, Ruan D, El-Senousey HAK, Chen W, Jiang S, Zheng C: Harmful effects and control strategies of aflatoxin B₁ produced by *Aspergillus flavus* and *Aspergillus parasiticus* strains on poultry: Review. *Toxins*, 11 (3): 176, 2019. DOI: 10.3390/toxins11030176
41. Karaman M, Özen H, Tuzcu M, Cığremiş Y, Önder F, Özcan K: Pathological, biochemical and haematological investigations on the protective effect of α-lipoic acid in experimental aflatoxin toxicosis in chicks. *Br Poult Sci*, 51(1): 132-141, 2010. DOI: 10.1080/00071660903401839